



RESENTING CLINICAL SIGNS

DATE

History: Panting and lethargic for 3 days. Tachycardic (HR >200) a few days ago. No murmur. Has been on grain-free diet. Started on Vetmedin 15 mg BID. ECG – atrial fibrillation. BNP >7000. Dilated hepatic veins and small-volume ascites.

8/23/21

ECHOCARDIOGRAPHIC FINDINGS

2D, M-mode, and Doppler study.

PERFORMED BY:

Dr. Brian Barnes

INTERPRETED BY

Keith Blass, DVM,
MS, DACVIM
(Cardiology)

There is mild left atrial dilation. The mitral valve appears normal, though there is Doppler evidence of mitral regurgitation present. There is mild left ventricular dilation. Left ventricular systolic function is mildly depressed. The aorta and aortic valve appear normal, though trace aortic insufficiency is present. Right atrial and right ventricular dimensions are normal. The tricuspid valve appears normal, though there is Doppler evidence of tricuspid regurgitation present. TR velocity is consistent with the presence of mild pulmonary hypertension (PG 35 mmHg). The pulmonary artery and pulmonic valve are normal. No shunting lesions are visualized. Trace pericardial effusion is present. No cardiac masses are seen.

ECG during echo: Sinus rhythm

PATIENT

Louie Banks

LA – 67.0 mm
LVIDd – 66.9 mm
LVIDs – 52.6 mm
FS – 21.3%
RA – 46.2 mm
LVOT – 1.16 m/s
RVOT – 0.73 m/s
TR – 2.97 m/s

SPECIES

Canine

BREED

Neopolitan Mastiff

ASSESSMENT/RECOMMENDATIONS

Dilated cardiomyopathy (DCM)

SEX

M

This examination demonstrates mild depression of Louie's left ventricular systolic function, consistent with DCM. Given his breed, it's possible that Louis could be suffering from a primary genetic-based form of the disease, however, given his history of receiving a grain-free diet, a diet-associated cardiomyopathy should be considered as well. Secondary to his myocardial dysfunction, with a possible contribution from his mitral regurgitation, Louie has mild dilation of his left heart chambers, as well as mild pulmonary hypertension. While Louie's radiographs showed no evidence of left-sided congestive heart failure, he is at risk for its development, therefore, continued monitoring of his respiratory rate/effort is recommended.

AGE

4 y

The ECG during Louie's echocardiogram showed no evidence of atrial fibrillation, however, it's possible that he could be experiencing it intermittently. Patients with myocardial dysfunction, especially those with atrial fibrillation, commonly develop right-sided congestive heart failure, therefore, I suspect this is the cause of Louie's mild ascites.

WEIGHT

78 kg

A whole blood or plasma taurine level is recommended, and taurine supplementation (1000 mg BID) should be given if a deficiency is documented. A Holter monitor may be warranted to determine how often Louie is in atrial fibrillation, as this may affect whether antiarrhythmic therapy is necessary. A switch to a traditional diet that does not contain peas, lentils, other legumes, or potatoes in the first 10 ingredients is recommended.

HOSPITAL NAME

Westview VH

REFERRING VET

Dr. Barnes

Louie's current therapy with pimobendan is warranted, though he would ideally be receiving 20 mg BID. Additional recommended therapy includes furosemide (150 mg BID), enalapril (37.5 mg BID), and spironolactone (75 mg BID).



A recheck physical exam and renal/electrolyte profile are recommended in 2 weeks. A recheck echocardiogram is in 6 months.

DATE

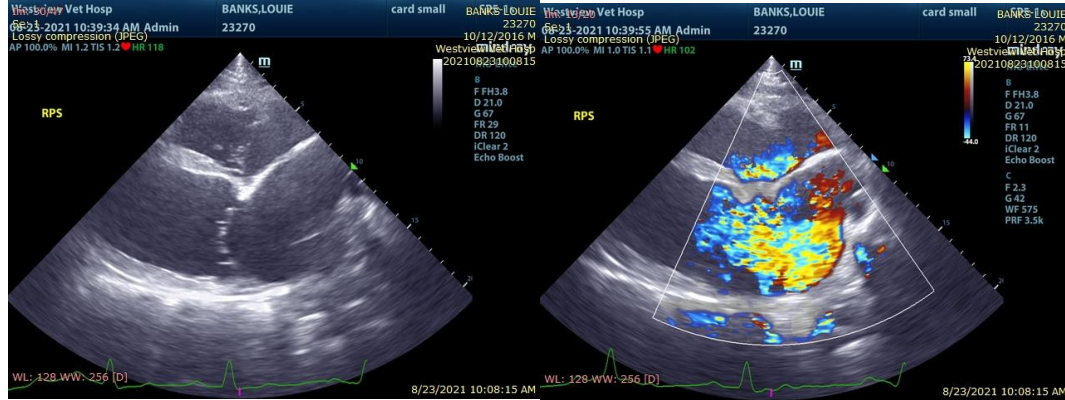
8/23/21

PERFORMED BY:

Dr. Brian Barnes

INTERPRETED BY

Keith Blass, DVM,
MS, DACVIM
(Cardiology)



PATIENT

Louie Banks

The information and recommendations provided are based on the images presented by the referring veterinarian. No evaluation can be communicated regarding pathology that was not visible in the image/video clips provided.

SPECIES

Canine

Thank you for this referral. If the clinical or image interpretation does not parallel your findings or if I can be of any further assistance please contact me.

BREED

Neopolitan Mastiff

Keith Blass, DVM, MS, DACVIM (Cardiology)
KeithBlass@gmail.com
631-804-5754

SEX

M

AGE

4 y

WEIGHT

78 kg

HOSPITAL NAME

Westview VH

REFERRING VET

Dr. Barnes